



**PATIENT**

Myah DeCoster

**PRESENTING CLINICAL SIGNS**

History: New grade I-II/VI systolic murmur. Elevated ProBNP 1,114. No clinical signs.

**SPECIES**

Canine

**ELECTROCARDIOGRAPHIC FINDINGS** \*Note: Single lead ECGs are evaluated as a rhythm strip. Morphology/MEA cannot be definitively commented on.

A single lead ECG is available; 25mm/s, 10mm/mV. The average heart rate is 110bpm (range 83-125bpm). The rhythm is sinus in origin, with a p for every QRS complex and vice versa. P and QRS morphologies are positive. Isolated VPCs are seen throughout; singles only. No supraventricular premature beats, pauses or other dysrhythmias observed. ECG diagnosis: Normal sinus rhythm with isolated VPCs.

**BREED**

Mix

**SEX**

Female Spayed

**ECHOCARDIOGRAM FINDINGS**

2D, m-mode, color flow and Doppler imaging is available.

**Left ventricle:** The LV diameter is normal with adequate myocardial function. LV wall thicknesses are normal.

**AGE**

13 years

**Left atrium:** The left atrium is normal.

**Mitral valve:** The mitral valve is normal with no prolapse into the left atrial lumen. Trace MR.

**WEIGHT**

55lbs

**Aortic valve/Aorta:** The aortic valve is normal in morphology and mobility. Normal aortic outflow velocity; laminar flow. No aortic insufficiency.

**Right ventricle:** Normal right ventricular diameter and morphology indicating no overt evidence of pulmonary arterial hypertension.

**Right atrium:** Normal RA dimension.

**Tricuspid valve:** The tricuspid valve appears normal with no tricuspid regurgitation.

**Pulmonic valve/Pulmonary artery:** The pulmonic valve is normal in morphology and mobility. No pulmonic insufficiency. Normal RVOT velocity; laminar flow.

**Pericardium/other:** No pericardial or pleural effusion noted. No obvious cardiac masses.

**INTERPRETED BY**

Maggie Machen  
Lamy, DVM  
DACVIM (Cardiology)

**2-Dimensional Measurements**

Ao diam (cm)	2.3
LA diam (cm)	2.4
LA:Ao (Swe)	1.1
IVS thickness (cm)	0.9
LVID diastole (cm)	3.5
PW thickness (cm)	0.8
LVID systole (cm)	2.4
FS (%)	32

**Doppler Measurements**

PV Vmax (m/s)	0.7
AoV Vmax (m/s)	1.3
MR Vmax (m/s)	NA
TR Vmax (m/s)	NA
TR PG (mmHg)	NA

**IMAGING**

**PERFORMED BY**

Pamela Harrigan,  
RDCS

**HOSPITAL NAME**

Falmouth Animal  
Hospital

**REFERRING VET**

Dr. Switzer

**INVOICE**

25648

**DATE**

8/8/22

**INTERPRETATION OF THE FINDINGS**

Overtly normal cardiac dimensions and function, with no obvious dysfunction or dilation of the left heart. No significant valvular leaks are visualized (trace MR is considered physiologic), and no evidence of pulmonary hypertension. If the murmur is ausculted consistently in the future or any signs of cardiac disease develop, reassessment is certainly advised. Prognosis is open at this time.

Isolated VPCs are seen on the ECG. VPCs are ectopic beats generated from abnormal conductive or fibrotic tissue in the ventricles of the heart muscle, and even frequent single



**PATIENT**

Myah DeCoster

VPCs will often cause no clinical signs in dogs. When sustained however, ventricular tachycardia can lead to symptoms such as lethargy and collapse.

**SPECIES**

Canine

VPCs are a very non-specific finding. They can be primary in origin (arrhythmic disease; a rule out diagnosis), develop secondary to significant cardiac disease (not present in this study), or be extra-cardiac in origin, i.e., due to pain, stress, inflammation, cancer, GI disease, DIC/sepsis, etc. In this 13-year-old dog without structural cardiac disease, ruling out all differentials can be considered including AUS. Unfortunately, there is always an elevated risk for collapse and sudden death in any arrhythmic patient, and even on medications this risk unfortunately still persists.

**BREED**

Mix

**SEX**

Female Spayed

In addressing arrhythmias in dogs, we must not only consider why they are happening as above, but also whether or not treatment is warranted. Given the mild nature of the arrhythmia, consider application of a holter monitor if interested in further evaluation. This will tell us the frequency and complexity of the rhythm over 24 hours of normal activity. An alternative approach would be to simply monitor at home for symptoms and utilize a holter monitor should the patient begin to experience clinical signs such as lethargy or collapse, which is also reasonable. Discussion with the owner is advised.

**AGE**

13 years

**WEIGHT**

55lbs

**RECOMMENDATIONS**

- No cardiac medications are clearly indicated at this time.
- Baseline BP is recommended.
- Consider holter monitor as discussed.
- Consider full systemic evaluation as discussed.
- Fish oil supplementation is recommended for dogs with arrhythmias (1000-2000mg of omega 3 and 6 once to twice daily).
- If further evaluation is not performed, anesthetic risk is considered moderately elevated. Avoid ketamine, telazol, Dexdomitor (or other alpha-2 agonists) and acepromazine. Recommend having lidocaine CRI available for use in the event of worsening ventricular arrhythmias under anesthesia (CRI 50–75mcg/kg/min).
- Monitor at home for collapse, exercise intolerance, and/or lethargy.

**INTERPRETED BY**

Maggie Machen  
 Lamy, DVM  
 DACVIM (Cardiology)

**IMAGING PERFORMED BY**

Pamela Harrigan,  
 RDCS

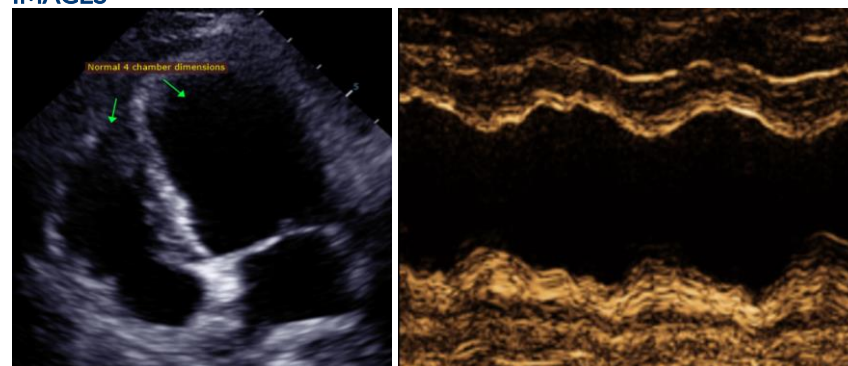
**PLAN**

If a holter monitor is elected, this will dictate whether additional therapy is needed and follow up protocol. If a holter is declined, recommend recheck ECG in 6 months.

**HOSPITAL NAME**

Falmouth Animal  
 Hospital

**IMAGES**



**REFERRING VET**

Dr. Switzer

**INVOICE**

25648

**DATE**

8/8/22

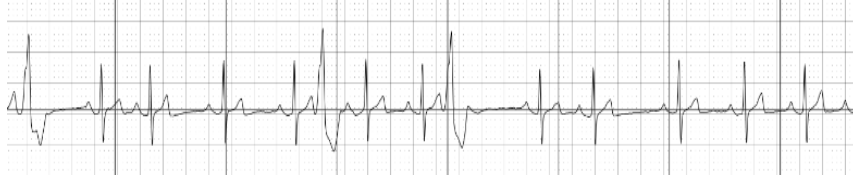


**PATIENT**

Myah DeCoster

**SPECIES**

Canine



**BREED**

Mix

The information and recommendations provided are based on the images presented by the referring veterinarian. No evaluation can be communicated regarding pathology that was not visible in the image/video clips provided.

**SEX**

Female Spayed

Thank you for this referral. This report was generated using transcription software, and minor dictation errors may be present. If the clinical or image interpretation does not parallel your findings or if I can be of any further assistance, please contact me.

**AGE**

13 years

Maggie Machen Lamy, DVM  
Diplomate of the American College of Veterinary Internal Medicine (Cardiology)  
info@sonopath.com

**WEIGHT**

55lbs

**INTERPRETED BY**

Maggie Machen  
Lamy, DVM  
DACVIM (Cardiology)

**IMAGING  
PERFORMED BY**

Pamela Harrigan,  
RDCS

**HOSPITAL NAME**

Falmouth Animal  
Hospital

**REFERRING VET**

Dr. Switzer

**INVOICE**

25648

**DATE**

8/8/22